



Case Study

Leading Interventionalist
Shares *mild*® Patient Outcomes

mild **Provider, Dr. Aaron Calodney**

Director Clinical Research, Precision Spine Care
Baylor Scott and White Texas Spine and Joint Hospital; Tyler, Texas



mild®

Patient History Pre-*mild*



71-Year-Old Male Patient

Medical History

CAD s/p CABG, HLD, HTN, chronic pain

Surgical History

Tonsillectomy, hernia repair, lumbar laminectomy L5-S1

Social History

Retired, former smoker, ~2 drinks EtOH/day

Allergies

Codeine

Medications

- Crestor 10 mg - daily
- Zantac 150 mg - daily
- Sildenafil 25 mg - daily
- Aspirin 325 mg - daily
- Testosterone propionate (bulk) powder - 1 daily
- Losartan 25 mg - daily

Spine History

- L5-S1 laminectomy in 1982, with excellent relief for many years
- Recently presented with back and leg pain compatible with spinal claudication
- Back pain VAS **8-10/10**. Pain worse with extended periods of walking, standing, or golf.
- Treated with epidural steroid injection and lumbar neurotomy with limited pain relief

Patient History Pre-*mild*



History as of May 2019

Patient returns for evaluation. C/o worsening low back pain.

Back Pain

VAS **2/10 with sitting**. Pain **8-10/10 with walking** with radiation bilaterally to buttocks.

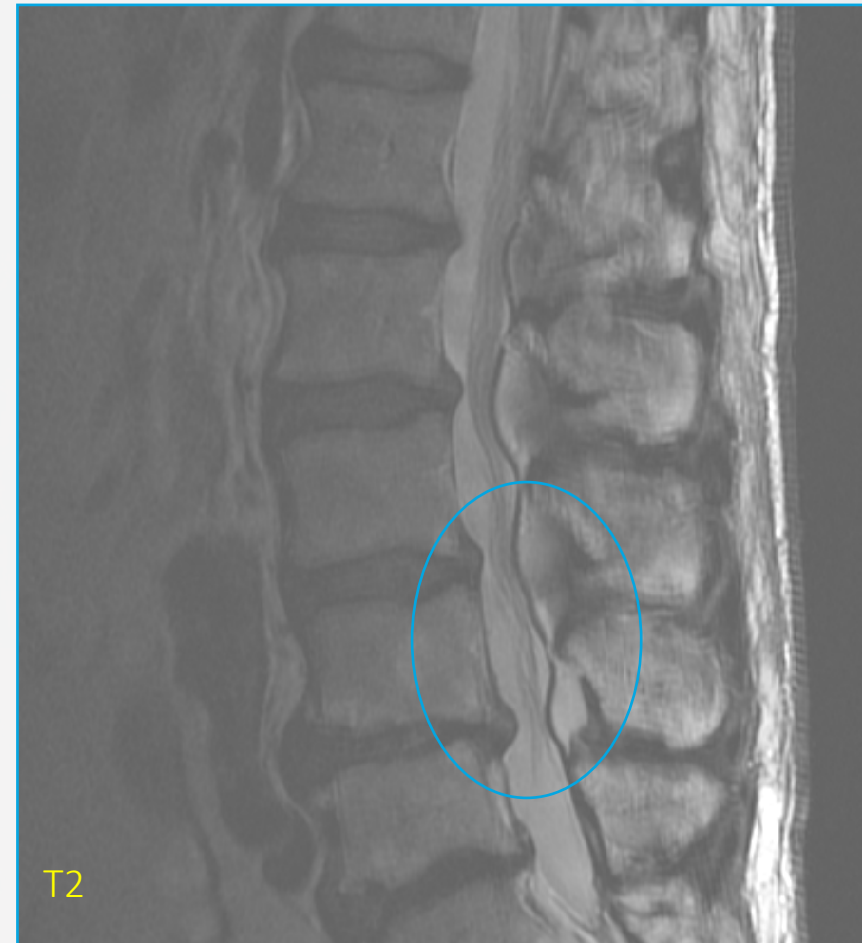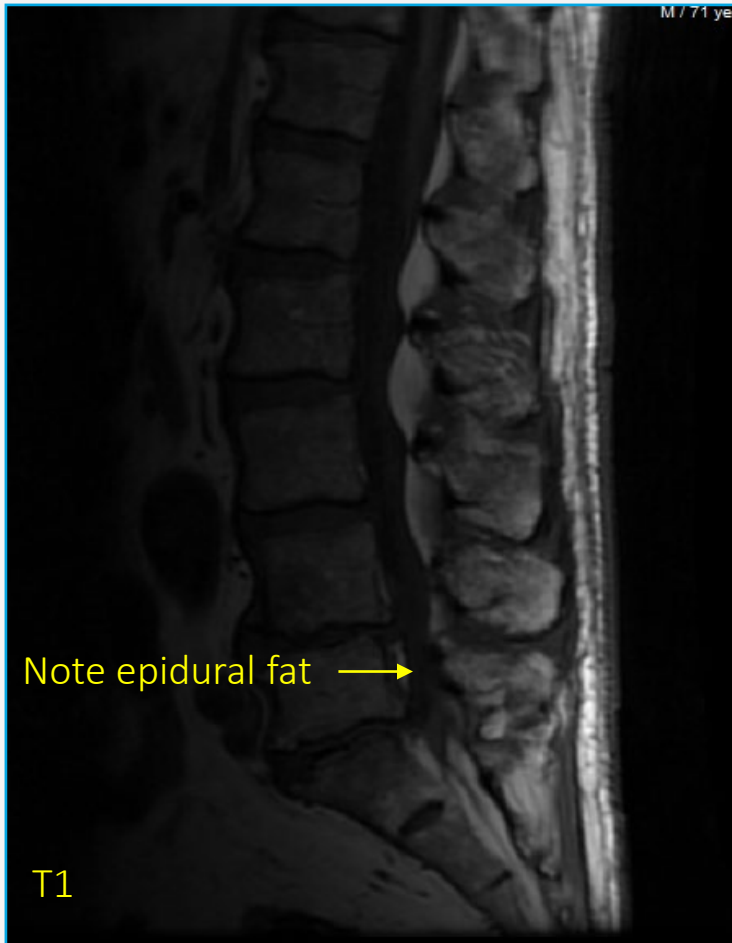
Symptoms of Neurogenic Claudication

- **Unable to stand or walk for > 5-10 minutes**; discomfort relieved with sitting or flexion

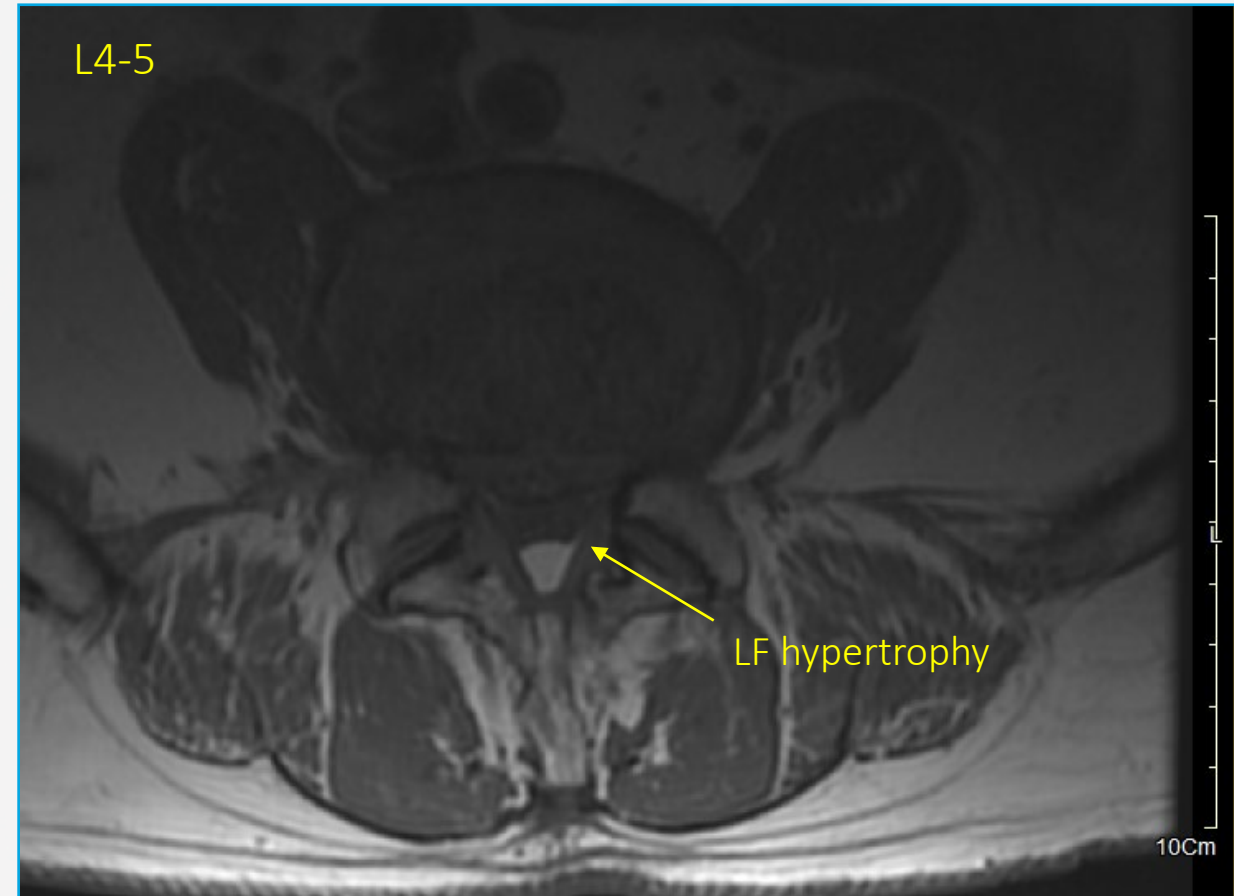
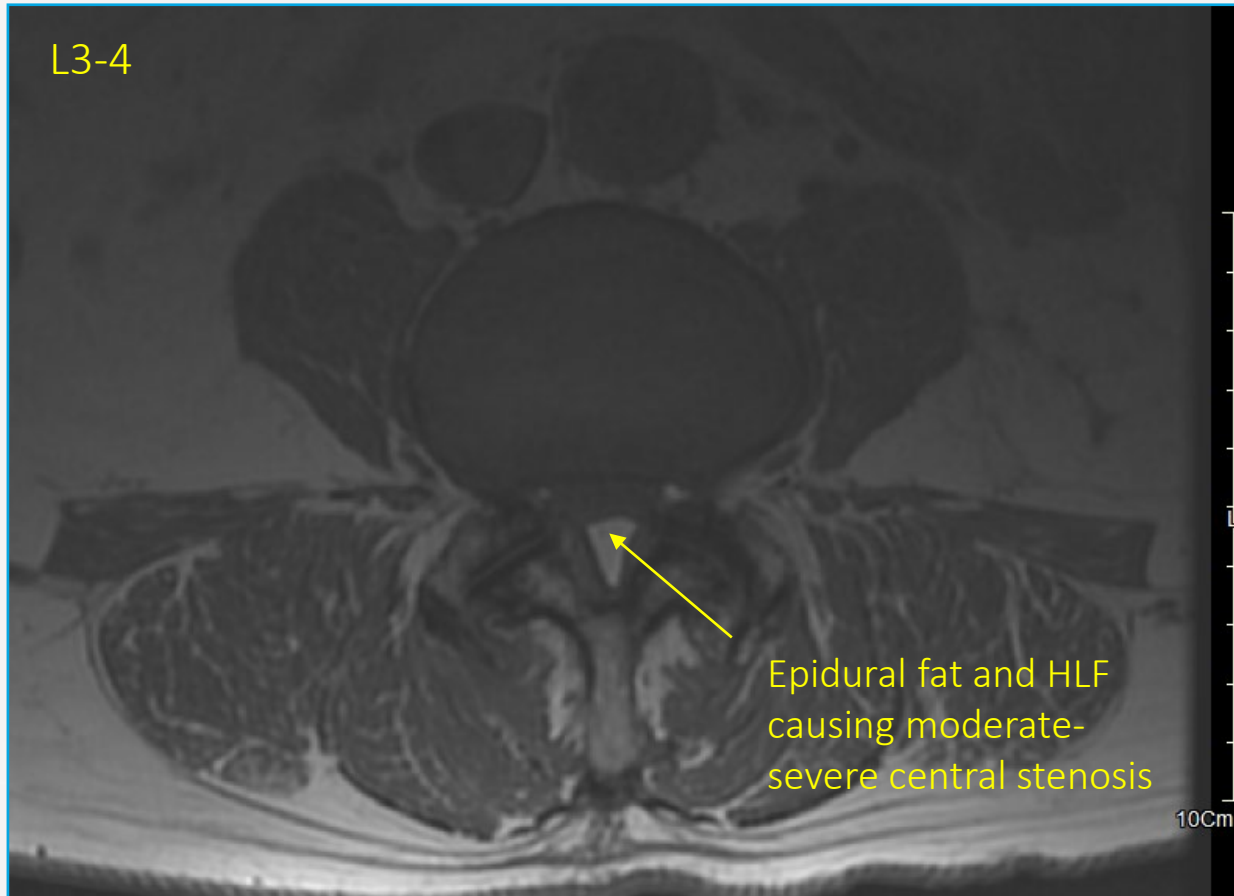
MRI

- Confirmed LSS with HLF at L3-L4 and L4-L5

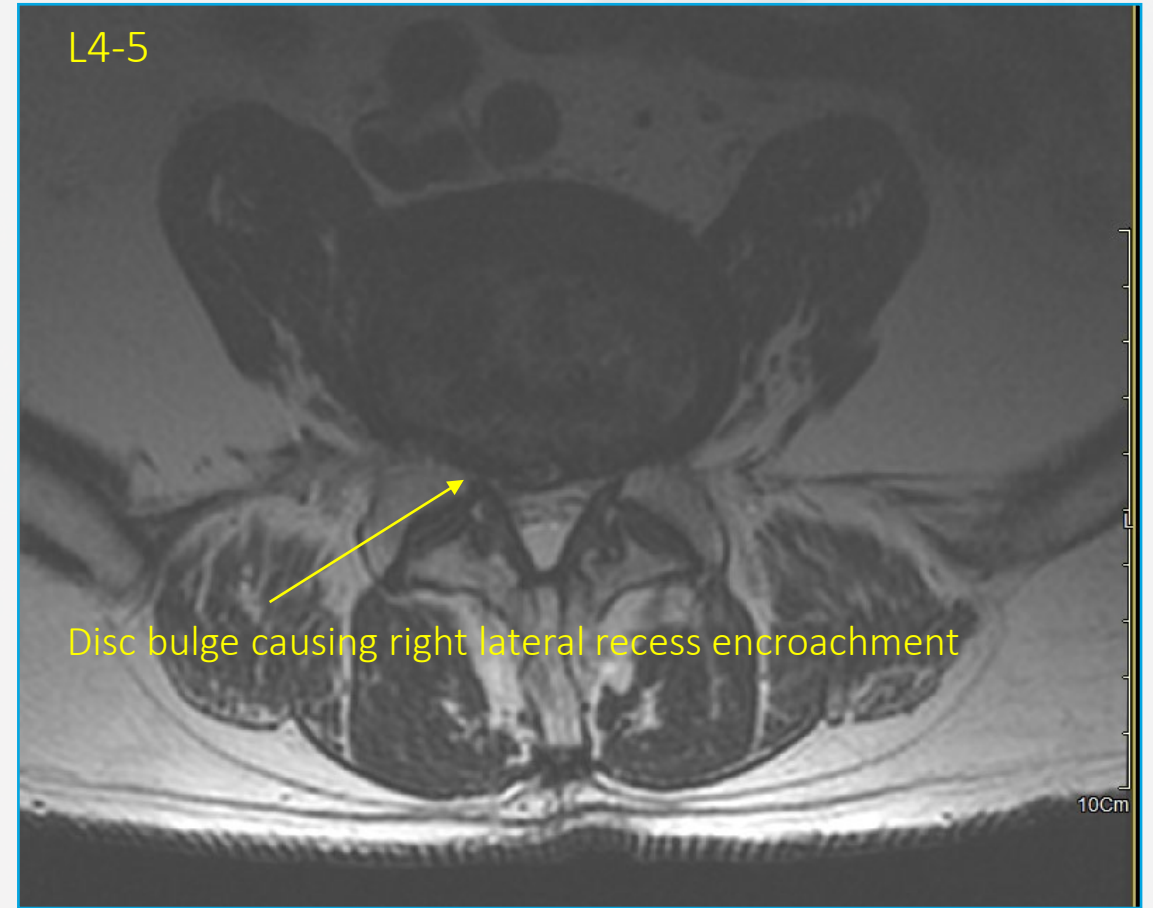
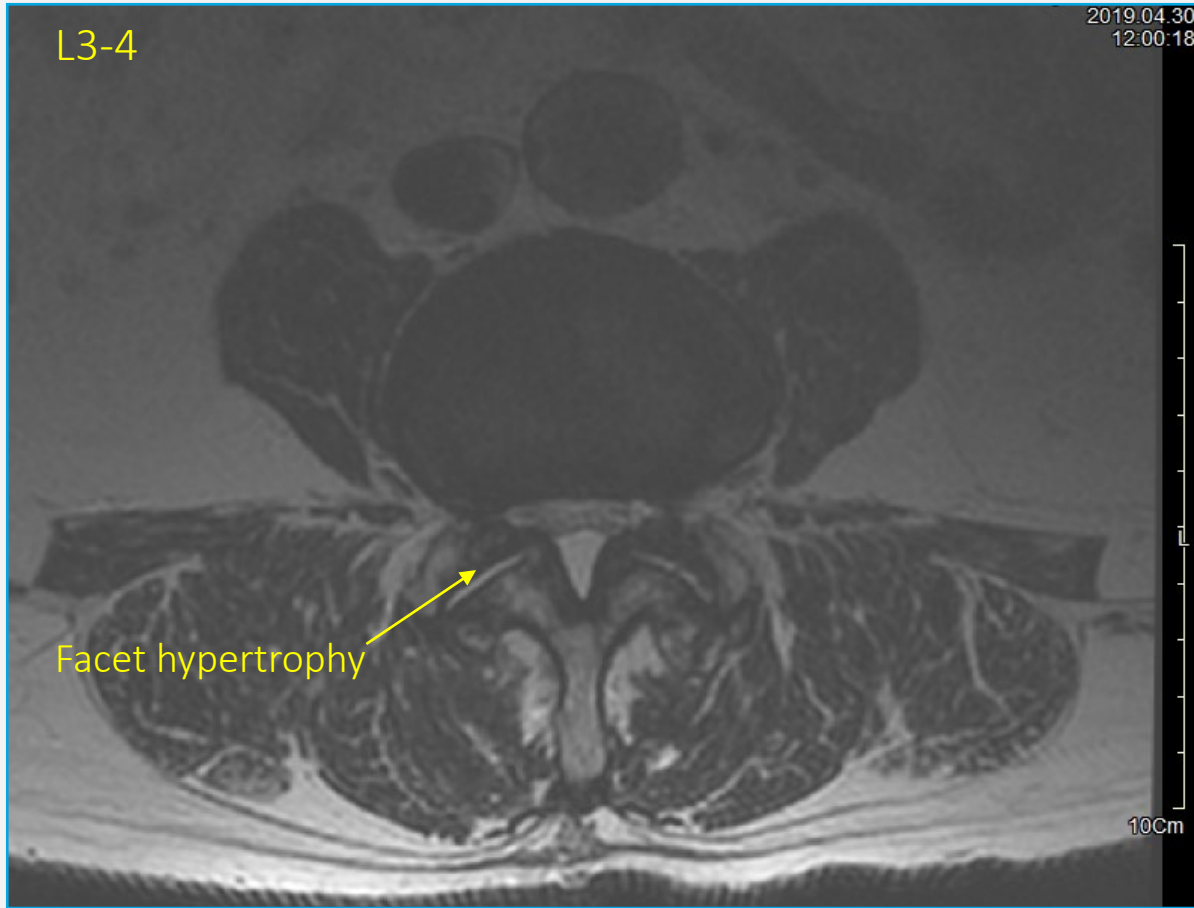
MRI Imaging – Sagittal Views



MRI Imaging – Axial T1



MRI Imaging – Axial T2

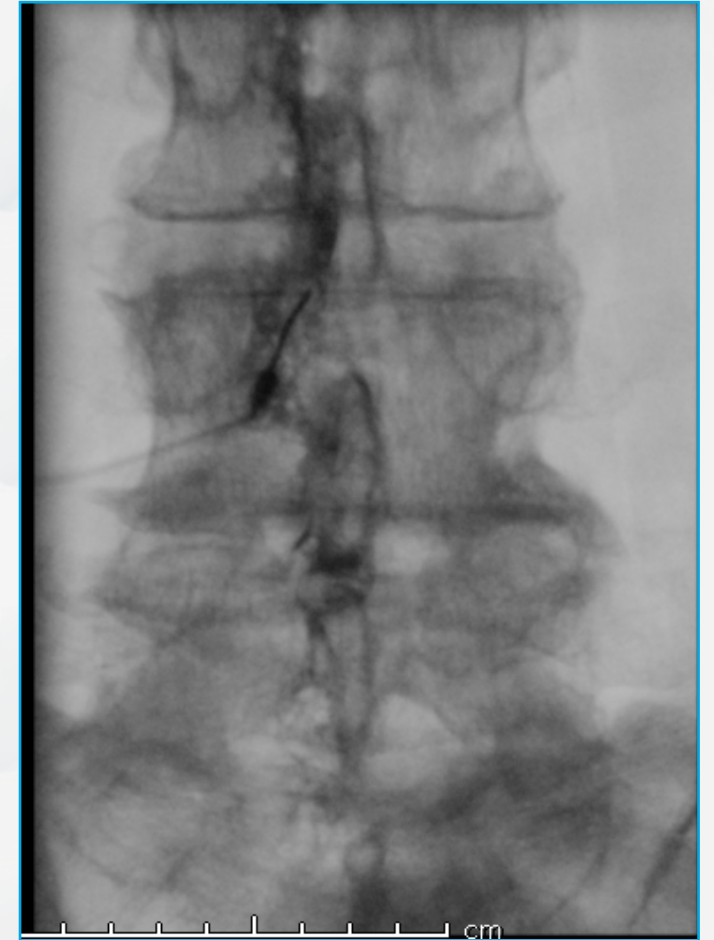
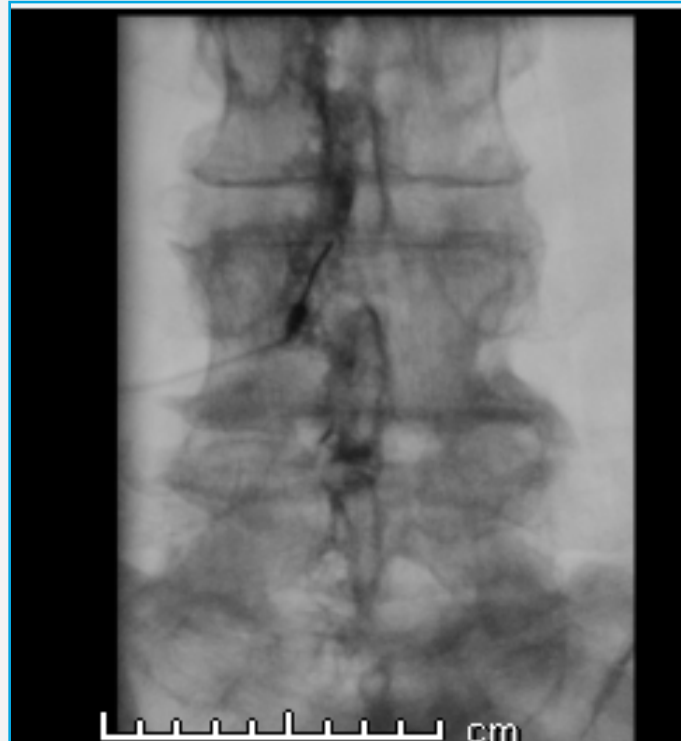
Procedure Details



Performed: 7/11/19

Levels Treated: Bilateral L3-4 & L4-5



Choose *mild*[®]

Before *mild*



Able to Stand/Walk

< 5-10 minutes



VAS 9/10



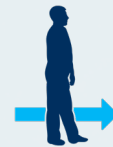> 10-year history of **LBP**, minimal response to ESI



QOL

Poor. Unable to stay active – wanted to golf again.

4 Weeks Post *mild*



Able to Stand/Walk

25 minutes



VAS 0/10



Meds

On no oral analgesics



QOL

Significant improvement. Able to golf with wife on a vacation 1 month post-op.

Key Takeaways

This patient went from being unable to stand for more than 5 – 10 minutes to playing golf one month after the procedure. He said that **The *mild* Procedure has enabled him to travel with his wife and play golf – his two favorite pastimes.**



Key Takeaways

This patient presented with multiple spinal comorbidities including lateral recess narrowing, facet arthropathy, and hypertrophic ligamentum flavum (HLF). By thinning just the HLF, we were able to provide him significant relief.

Disclaimer

This material is provided for guidance and/or illustrative purposes only and should not be construed as a guarantee of future results or a substitution for legal advice and/or medical advice from a healthcare provider. This material is provided for general educational purposes only and should not be considered the exclusive source for this type of information. Vertos Medical does not practice medicine and assumes no responsibility for the administration of patient care. At all times, it is the professional responsibility of the practice or clinical practitioner to exercise independent judgment. Results may vary.

mild[®]

